

Histological structure of pancreas in normal control, diabetic control and extract treated *Albino* rats

Kinkar Shobha Bhanudas¹ and Patil Kishor Gopal^{2*}

¹PGT Department of Zoology, RTM Nagpur University, Nagpur (M.S.) India PIN-4400010.

²Department of Zoology, Government Institute of Science, R. T. Road Civil Lines, Nagpur (M.S.) India PIN-440 001.

*Corresponding author E-mail- drkgpatil@gmail.com

Manuscript details:	ABSTRACT
<p>Received: 02.02.2016 Accepted: 08.03.2016 Published : 11.04.2016</p> <p>Editor: Dr. Arvind Chavhan</p> <p>Cite this article as: Kinkar Shobha Bhanudas and Patil Kishor Gopal (2016) Histological structure of pancreas in normal control, diabetic control and extract treated <i>Albino</i> rats, <i>International J. of Life Sciences</i>, 4(1): 78-82.</p> <p>Copyright: © 2016 Author(s), This is an open access article under the terms of the Creative Commons Attribution-Non-Commercial - No Derivs License, which permits use and distribution in any medium, provided the original work is properly cited, the use is non-commercial and no modifications or adaptations are made.</p>	<p>The present study is carried out to investigate the structure of pancreas in normal control, diabetic control and <i>Tinospora cordifolia</i> extract treated albino rats. Healthy albino rats (9 months old) of both the sexes, weighing 150-190gm were used for the experiment. Rats were treated with <i>Tinospora cordifolia</i> whole plant extract 20ml/kg body weight, twice a day from day 2 to 30. It was observed that the cells in the pancreas in normal control animals are densely packed. In case of alloxan treated group the cell density significantly diminish. Where as in case of <i>Tinospora cordifolia</i> extract treated group it was observed that the empty spaces in islets created by the alloxan induced necrosis is significantly decreased.</p> <p>Keywords: Insulin, diabetes, <i>Tinospora cordifolia</i>, albino rats.</p> <p>INTRODUCTION</p> <p>Present study is carried out on albino rat <i>Rattus norvegicus</i> due to its metabolic relatedness with human. von Mering and Minkowski found that removing the pancreas from dogs resulted in fatal diabetes, providing the first clue that the pancreas plays a key role in regulating glucose concentrations (von Mering and Minkowski, 1890; Brogard <i>et al.</i>, 1992). In 1910, Edward Albert Sharpey-Schafer hypothesized that diabetes was due to the deficiency of a single chemical produced by the pancreas; he called this chemical insulin, from the Latin word <i>insula</i>, meaning island and referring to the pancreatic islet cells of Langerhans. In 1921, Banting and Best actually discovered insulin when they reversed diabetes that had been induced in dogs with an extract from the pancreatic islet cells of healthy dogs (Banting <i>et al.</i>, 1991 and Bliss 2007). Together with Collip and Macleod, they purified the hormone insulin from bovine pancreases and were the first to use it to treat a patient with diabetes.</p> <p>Management of diabetes without any side effects is still a challenge in the medical field, as presently available drugs for diabetes have one or more</p>

adverse effects. Since the existing drugs for the treatment of diabetes mellitus do not satisfy our need completely, the search for new drugs continues. In recent years, herbal remedies for the unsolved medical problems have been gaining importance in the research field. Thus, this study was undertaken to explore the efficacy of anti-diabetic activity of *Tinospora cordifolia* in diabetic rats.

It is estimated that 366 million people had diabetes mellitus in 2011; by 2030 this would have risen to 552 million (Brussels, 2011). The number of people with type 2 diabetes mellitus is increasing in every country with 80% of people having diabetes mellitus living in low and middle income countries. Diabetes mellitus caused million deaths in 2011. It is estimated that 439 million people would have type 2 diabetes mellitus by the year 2030. The incidence of type 2 diabetes mellitus varies substantially from one geographical region to the other as a result of environmental and lifestyle risk factors (Zimmet *et al.*, 2001). The International Diabetes Federation estimates the total number of diabetic subjects to be around 40.9 million in India and this is further set to rise to 69.9 million by the year 2025 (Sicree *et al.*, 2006). A study done in Small Township in south India reported a prevalence of 5% (Ramachandran *et al.*, 1988).

The serum insulin level decreased significantly in the alloxan treated group. In the *Tinospora cordifolia* whole plant extract treated group the insulin level reverse to normal. The hike in insulin secretion observed in this study from diabetic control to the normal as observed in *Tinospora cordifolia* treated group indicates that the whole plant extract may exerts its healing effect on the islets of Langerhans (Kinkar and Patil, 2015; 2016).

MATERIALS AND METHODS

Tinospora cordifolia is a large, glabrous, deciduous climbing shrub native to India. The stems are rather succulent with long filiform fleshy aerial roots from the branches. The plant material was collected from hygienic places from in and around the Nagpur city, Soxhlet apparatus was used for the preparation of concentrated extract of *Tinospora cordifolia*. The plant material *Tinospora cordifolia* was collected from hygienic places from in and around the Nagpur city and identified. The collected plant material was

washed with water in order to make it free of dirt and other impurities and was shade dried. Shade dried whole Plant material was grind with mortar and pestle into the fine powder and alcoholic and aqueous extract of *Tinospora cordifolia* was prepared according to the standard procedure.

Healthy albino rats (9 months old) of both the sexes , weighing 150-190gm were used for the experiment. Animals were free to access drinking water and food. Animals were cared for and used in accordance with the Institutional Animal Ethics Committee (IAEC), P.G.T. Department of Zoology, RTM Nagpur University, Nagpur (Registration No.-478/01/a/CPCSEA).

For experimental induction of diabetes alloxan monohydrate (A74/3 Sigma Aldrich) was used. Diabetes was induced in 16 hrs fasted albino rats with single intraperitoneal dose of alloxan monohydrate. Alloxan injection was prepared in 0.9% normal saline. Rats with fasting blood glucose more than 220 mg/dl was considered for study. During dose standardization study it was found that 180 mg /kg intraperitoneal dose of alloxan monohydrate was suitable for diabetes induction with the 6-12 month old rats.

Experimental Animals

Healthy albino rats (9 months old) of both sexes, weighing 150-190 gm were used for the experiment. Animals were free to access drinking water and food. Animals were cared for and used in accordance with the Institutional Animal Ethics Committee (IAEC), P.G.T. Department of Zoology, RTM Nagpur University, Nagpur (Registration no.-478/01/a/CPCSEA).

For experimental induction of diabetes alloxan monohydrate (**A7413 Sigma Aldrich**) was used. Diabetes was induced in 16 hrs fasted albino rats with single intraperitoneal dose of alloxan monohydrate.

Grouping of animals

For this study rats were divided into three groups (n=6),

Group-I (NC): Kept as normal control (NC) the animals of this group was free to access drinking water and food they neither injected by alloxan nor fed on plant extract.

Group- II (DC): These group animals were injected with alloxan monohydrate (180 mg/kg bw) and kept as diabetic control. They were not fed on extract.

Group III (DC+TCE): This group was injected with alloxan monohydrate (180 mg/kg bw) and from day 2 to 30 half an hour prior to feeding, orally administered with TCE (20 ml/kg bw) twice a day.

Histological study of pancreas

After 30 days of plant extract dosing, animals from each group were sacrificed, pancreases were dissected out and fixed in Baker's formalin. After adequate fixation tissues are transferred to 70% ethanol. Tissue is dehydrated through a series of graded ethanol baths during these the serial changes of 30%, 50%, 70%, 90% and then first change to absolute, second change for absolute was given to displace the water. After completion of dehydration the tissue was then transferred to the first exposure to xylene as clearing agent after half an hour the second change of the xylene was given. The tissue was then infiltrated with two changes of paraffine wax at 60°C. The infiltrated tissue was then embedded into wax blocks. A well trimmed paraffine block of pancreases tissue was sectioned on rocking microtome at 6 μ . The ribbon of the tissue were spread over the slide with Mayer's albumin and allowed the slide for drying. After three days the slides were process for staining.

For staining with aldehyde fuchsin the slides were deparaffinized with two changes of xylene and preceded for hydration with changes of 100% - water grades. After hydration slides were kept into 30% 50% and 70% ethanol for 10 minutes each. After this slides were kept in aldehyde fuchsin (AF) solution for half an hour. After staining with AF three changes of 70% was given for 3 min., 2 min., 1 min. respectively. The slides were then washed in tap water for approximately 15 minutes. Stained in Mayer's Hematoxylin for 10 seconds. Again wash in running tap water for oxidation of the hematoxylin stain and observed for blue colour development. Then three dips in 50% alcohol were given this followed by three dips in eosin. The slides were then processed for quick dehydration by placing the slides into 95% ethanol for 10 minutes and then to absolute ethanol. After dehydration three changes of xylene were given. Mounting was done with Di-n-butyl phthalate in Xylene (DPX).

RESULTS AND DISCUSSION

The significant ($P < 0.05$) hike in insulin secretion observed in this study from diabetic control to the

normal as observed in *Tinospora Cordifolia* treated group indicates that the whole plant extract may exerts its healing effect on the islets of Langerhans. To confirm this we have performed the histological staining of pancreatic section with aldehyde fuchsin.

According to Puranik (2010) the antidiabetic activity of *Tinospora Cordifolia* stem extract is not through the insulin secretion by pancreatic beta cells. They observed that *Tinospora cordifolia* treated diabetic rats did not reveal any evidence of regeneration of beta cells of islets of Langerhans. The histological section of the pancreas of the drug treated control rats showed the normal architecture of the islets of Langerhans with the granulated beta cells appearing dark. The histology of the pancreas in diabetic rats showed small and shrunken islets of Langerhans. Destruction of beta cells was observed in this section. The histology of the pancreas in *Tinospora cordifolia* treated diabetic rats showed a similar architecture to that of diabetic rats. There was no considerable change in the architecture of the islets of Langerhans after the *Tinospora cordifolia* treatment. It appears that there was no regeneration of beta cells after the *Tinospora cordifolia* treatment; therefore, it appears that the antihyperglycemic activity of *Tinospora cordifolia* is not through the insulin secretion and is independent of insulin secretion by pancreatic beta cells.

In the histological observation it was observed that the cells in the normal control animal pancrease islets was densely packed (Fig. 1). In case of alloxan treated group the cell density significantly diminish as denoted by the arrows in the (Fig. 2). The photomicrograph of the diabetic pancreatic islets clearly shows the alloxan induced damage in the form of the empty spaces. This spaces may be created due to the alloxan induced necrosis of the beta cells. As discussed previously the alloxan induced necrosis is mediated by reactive oxygen species mediated lipid peroxidation which causes bursting of plasma membrane of the cell and disturbance of osmotic balance this osmotic alteration ultimately leads the cell towards necrosis. In contrast to previous work on the *Tinospora Cordifolia* stem extract in present study we observed the healing effect of the *Tinospora Cordifolia* whole plant extract. From (Fig. 3) photomicrograph it is observed that the empty spaces in islets created by the alloxan induced necrosis is significantly decreased, this indicates that *Tinospora Cordifolia* whole plant extract stimulates the regeneration of the alloxan damaged islets.

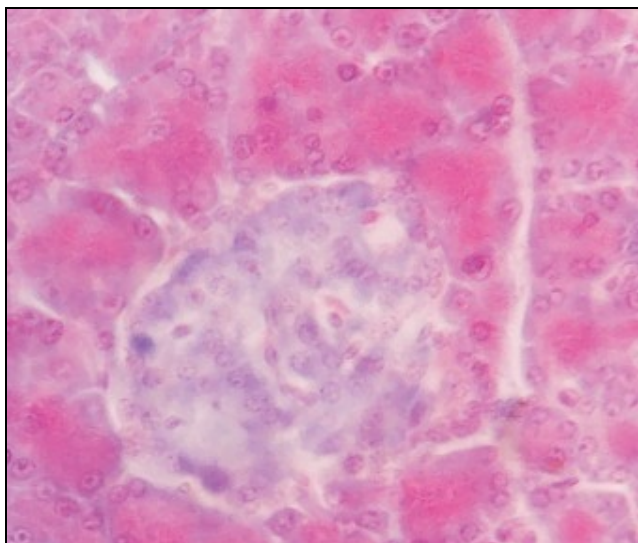


Fig. 1:

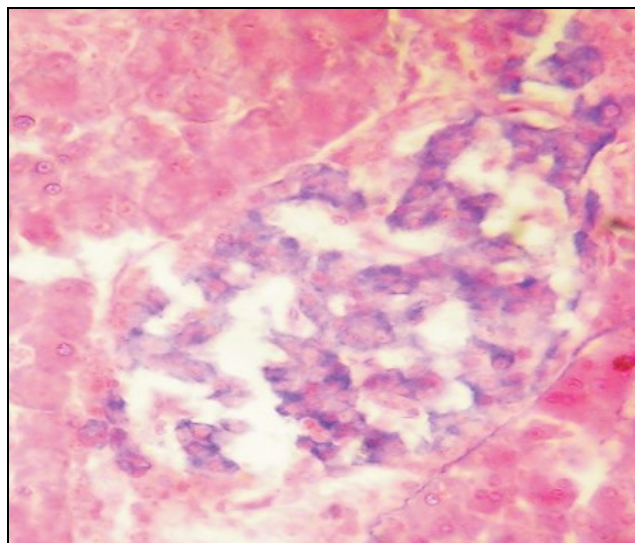


Fig. 2

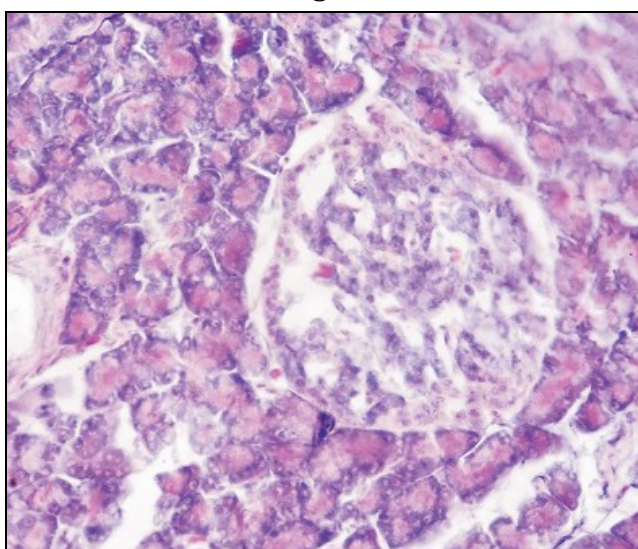


Fig 3

Fig. 1: Aldehyde fuschin stained rat pancreas photomicrograph of the normal control group. Arrow indicates healthy islets of Langerhans. X450

Fig. 2: Aldehyde fuschin stained rat pancreas photomicrograph of the diabetic control group. Arrow indicates the alloxan induced damage. X450

Fig. 3: Aldehyde fuschin stained rat pancreas photomicrograph of the diabetic control group. Arrow indicates damage remain after the *Tinospora cordifolia* extract treatment. X450

In nutshell, the *Tinospora cordifolia* whole plant part extract shows hypoglycemic activity in the alloxan induced diabetes. This hypoglycemic activity of the plant extract is not because of the insulin mimicking activity. *Tinospora cordifolia* whole plant part extract stimulate the pancreatic islets regeneration as observed during the histological photomicrograph. The plant extract induced regeneration of the islets responsible for the increase in the serum insulin. In addition to these activities the *Tinospora cordifolia* extract shows protective activity in (Reactive Oxygen Species) ROS induce damage tissues.

CONCLUSION

This study was carried out to explore the efficacy of anti-diabetic activity of *Tinospora cordifolia* whole plant extract in alloxan induced diabetic rats. The hike in insulin secretion observed in this study from diabetic control to the normal as observed in *Tinospora cordifolia* treated group indicates that the whole plant extract may exerts its healing effect on the islets of Langerhans. To confirm this we have performed the histological staining of pancreatic section with aldehyde fuschin.

The study of antidiabetic activity of the *Tinospora Cardifolia* whole plant part extract was carried out on the albino rats of both the sexes. The rats were grouped into three group i.e. normal control, diabetic control and treatment group respectively. Experimental diabetes was induced with alloxan 180 mg/kg intraperitoneal dose.

From the present study it can be concluded that the *Tinospora cordifolia* whole plant extract possesses antidiabetic activity which is not by insulin mimicking activity of bioactive compound instead, it is mediated by regeneration of islets of Langerhans. Beside its antidiabetic and regeneration stimulating activity on damage pancreatic Islets the plant extract found to contain the bioactive principle which prevents reactive oxygen species mediated oxidative damage.

In the histological observation it was observed that the cells in the normal control animal pancreas Islets was densely packed (Fig. 1). In case of alloxan treated group the cell density significantly diminish as denoted by the arrows in the (Fig. 2). The photomicrograph of the diabetic pancreatic islets clearly shows the alloxan induced damage in the form of the empty spaces. This spaces may be created due to the alloxan induced necrosis of the beta cells. As discussed previously the alloxan induced necrosis is mediated by reactive oxygen species mediated lipid peroxidation which causes bursting of plasma membrane of the cell and disturbance of osmotic balance this osmotic alteration ultimately leads the cell towards necrosis. In contrast to previous work on the *Tinospora cordifolia* stem extract in present study we observed the healing effect of the *Tinospora cordifolia* whole plant extract. From (Fig. 3) photomicrograph it is observed that the empty spaces in islets created by the alloxan induced necrosis is significantly decreased, this indicates that *Tinospora cordifolia* whole plant extract stimulates the regeneration of the alloxan damaged islets.

treatments of diabetes mellitus: Primary report, CMAJ; 145:1281-1286.

Johnson DD (1950) Alloxan administration in the guinea pig: a study of the regenerative phase in the islets of Langerhans. *Endocrinology*; 47: 393-98.

Kinkar SB and Patil KG (2015) Antidiabetic Activity of *Tinospora Cordifolia* (Fam: Menispermaceae) in Alloxan Treated Albino Rats. *Applied Science Journal*, 1 (5): 316-319.

Kinkar SB and Patil KG (2016) Investigations on Insulin Levels and Blood Sugar Concentration in *Tinosporacordifolia* Extract Treated Albino Rats. *World Journal of Zoology*, 11(1): 155-158.

Kliber A, Szkudelski T, Chichlowska J (1996) Alloxan stimulation and subsequent inhibition of insulin release from in situ perfused rat pancreas. *Journal of Physiology and Pharmacology*; 47: 321-8.

Mythili MD, Vyas R, Akila G, Gunasekaran S (2004) Effect of Streptozotocin on the ultrastructure of rat pancreatic islets. *Microsc Research Technology*; 63: 274-81.

Peschke E, Ebel H, Bromme HJ, Peschke D (2000) Classical and new diabetogens comparison of their effects on isolated rat pancreatic islets in vitro. *Cell Molecular Life Science*; 57: 158-64.

Ramachandran A, Jali MV, Mohan V, Snehalatha C, Viswanathan M (1988) High prevalence of diabetes in an urban population in south India. *Biomedical Journal*; 297:587-90.

Sicree R, Shaw J, Zimmet P (2006) Diabetes and impaired glucose tolerance. In: Gan D, editor. *Diabetes atlas*. International diabetes federation. 3rd ed. Belgium: International Diabetes Federation; 15-103.

Tinospora cordifolia stem bark (2006) Traditional system of medicine. New Delhi: Narosa Publishing House; 414-7.

Von Mering J, Minkowski O (1890) Diabetes mellitus nach Pankreasextirpation. *Archiv For Experimentelle Pathologie And Pharmacology*; 26: 371-87.

Zimmet P, Alberti KG, Shaw J (2001) Global and societal implications of the diabetes epidemic. *Nature*; Dec; 414 (6865): 782-787.

REFERENCES

Brogard JM, Vetter T, Bickle JF (1992) Discovery of pancreatic diabetes in Strasbourg. *Diabetes Metabolism*; 18: 104-114.

Bliss M (2007) The discovery of insulin. University of Chicago Press, Chicago.

Banting FG, Best CH, Collip JB, Campbell WR, Fletcher AA. 1991. *Encore: pancreatic extract in the*